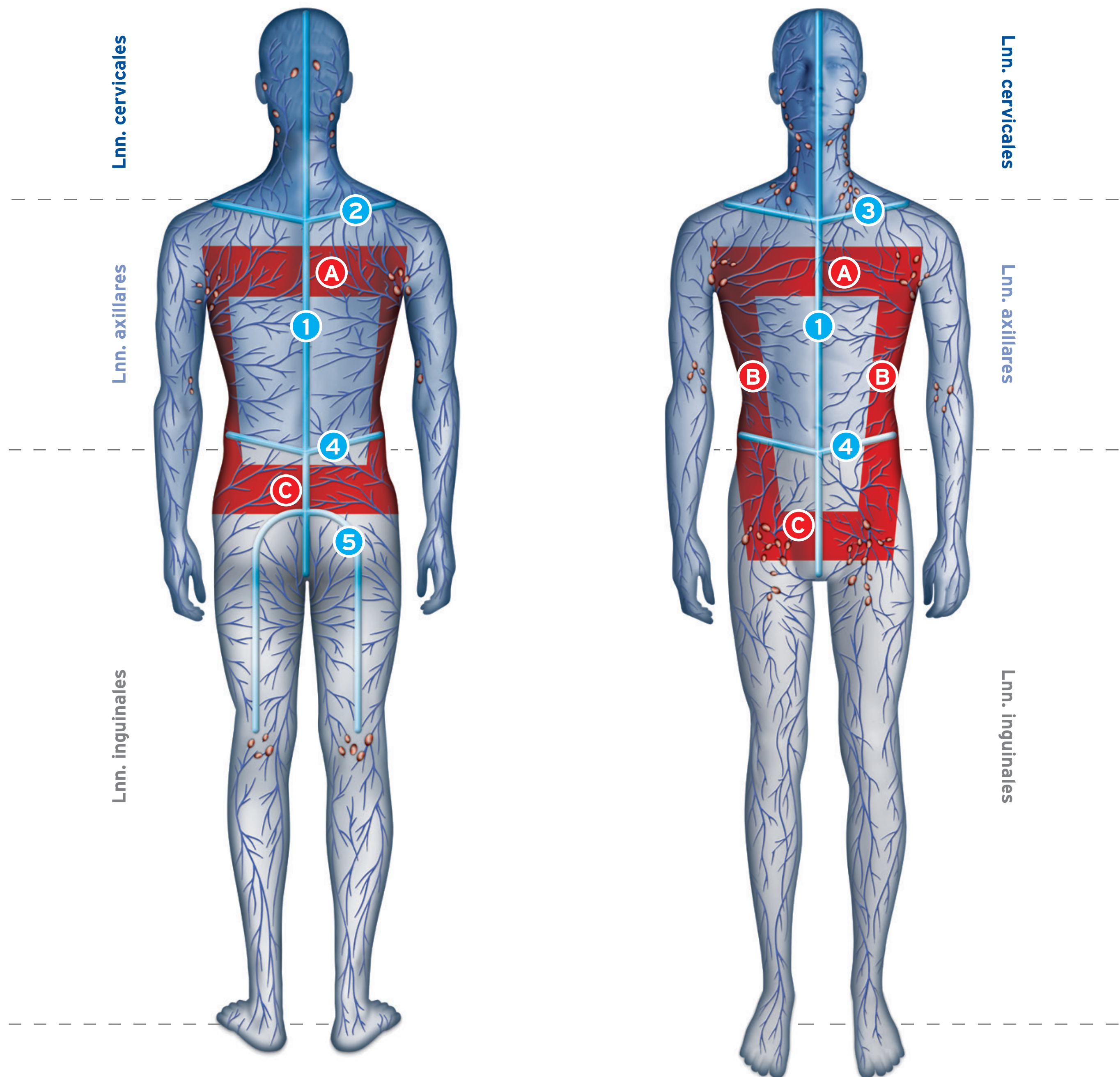



Lymphatic Watersheds and Anastomoses



Watersheds


- 1 Median Sagittal (anterior and posterior)
- 2 Spine of Scapula (Posterior Upper Horizontal/Transverse)
- 3 Clavicle (Anterior Upper Horizontal/Transverse)
- 4 Horizontal/Transverse (anterior and posterior)
- 5 Gluteal



The lymph is transported from the initial lymphatic vessels to the lymph collectors and from there to the regional lymph nodes. The drainage areas are separated from each other by "drainage divides".

Anastomoses

- A Interaxillary
- B Axillo - inguinal
- C Interinguinal



Manual lymph drainage makes use of the anastomoses connecting the different lymph areas to each other allowing lymph to be transported across the divides into edema-free areas.